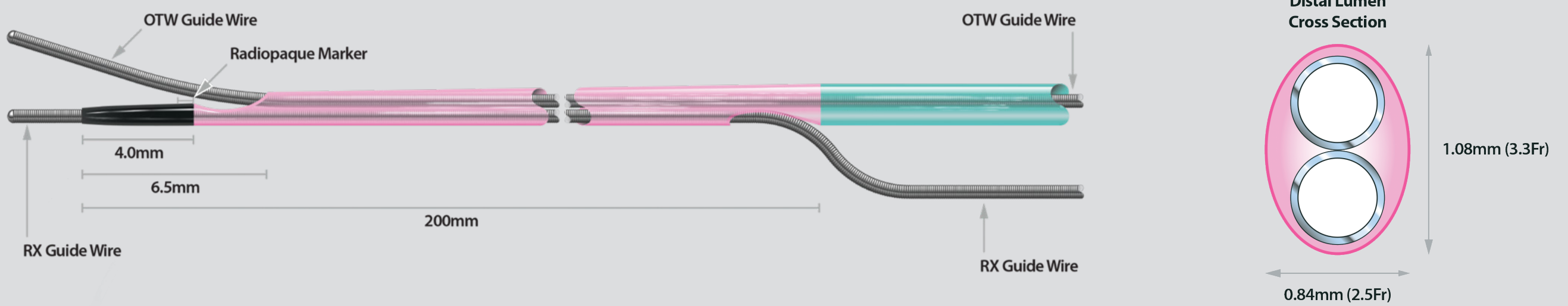



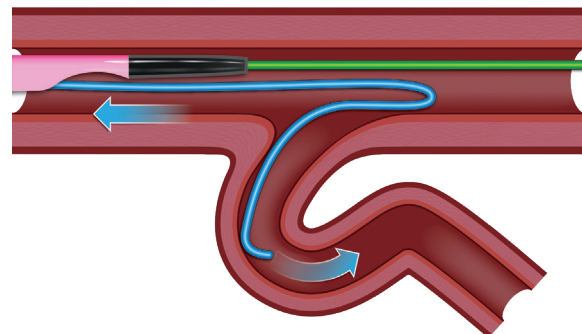
ASAHI SASUKE



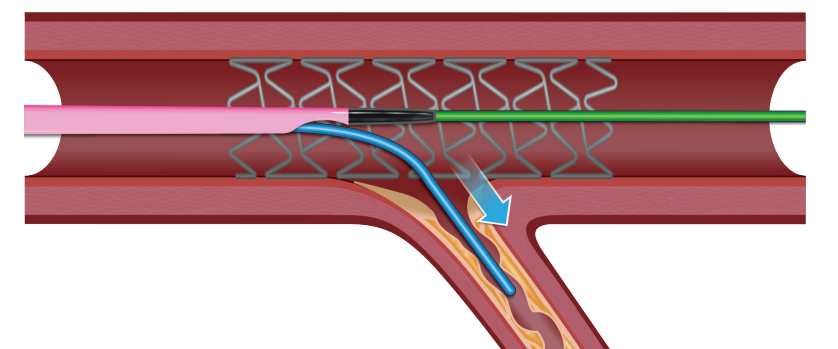
1. Subintimal Anchor Technique



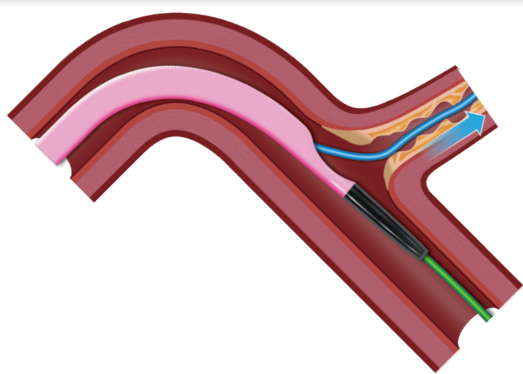
2. Reverse Wire Technique



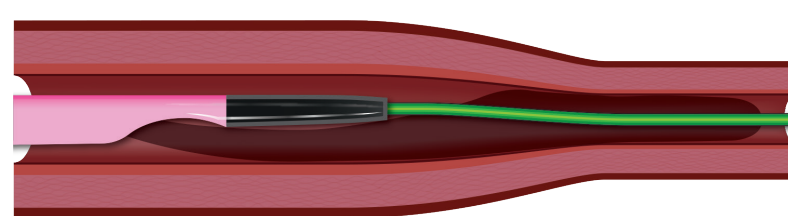
3. Side Branch Access through Stent Strut



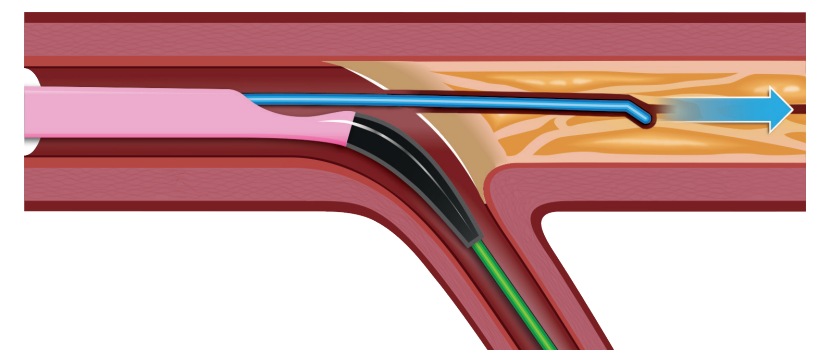
4. Access to Side Branch Occlusion



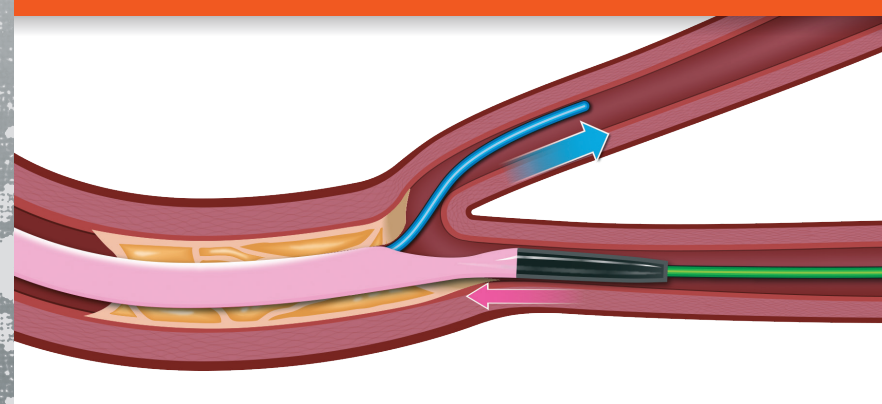
5. Selective Contrast Injection



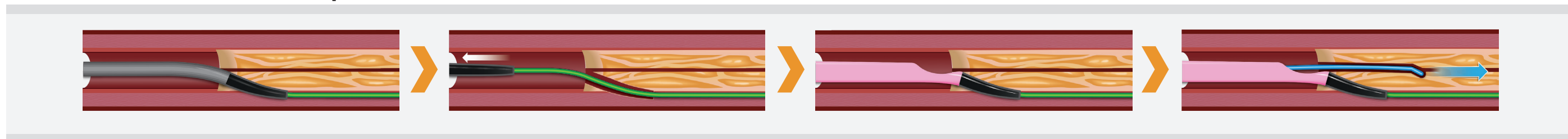
6. Side Branch Anchor Technique



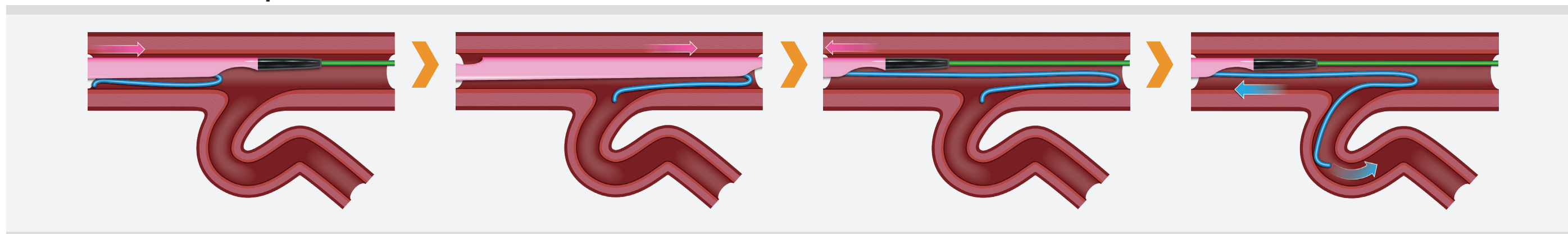
7. Protection of Side Branch



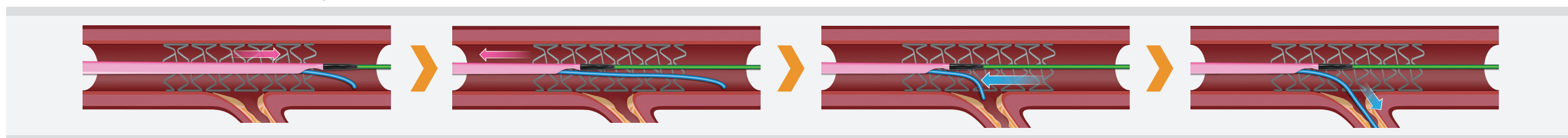
1. Subintimal Anchor Technique




2. Reverse Wire Technique



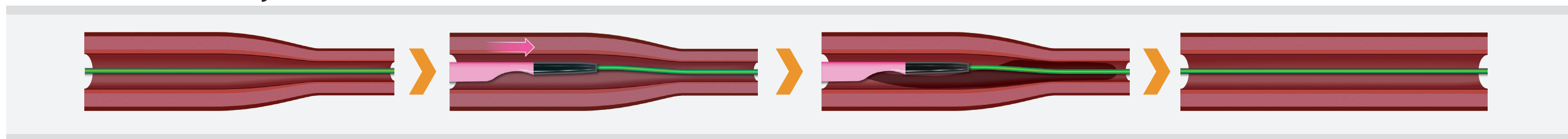
3. Side Branch Access Through Stent Strut



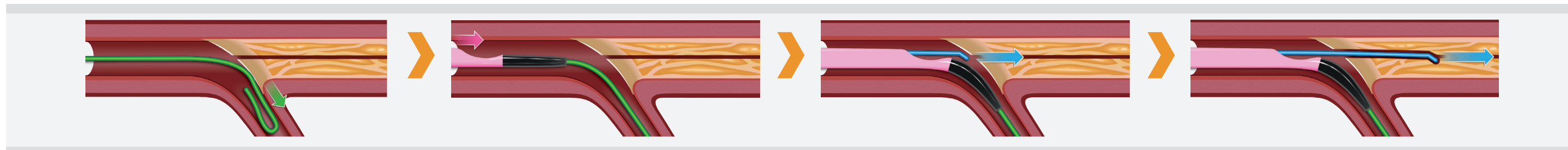
4. Access to Side Branch Occlusion



5. Selective Contrast Injection



6. Side Branch Anchor Technique



7. Protection of Side Branch

